

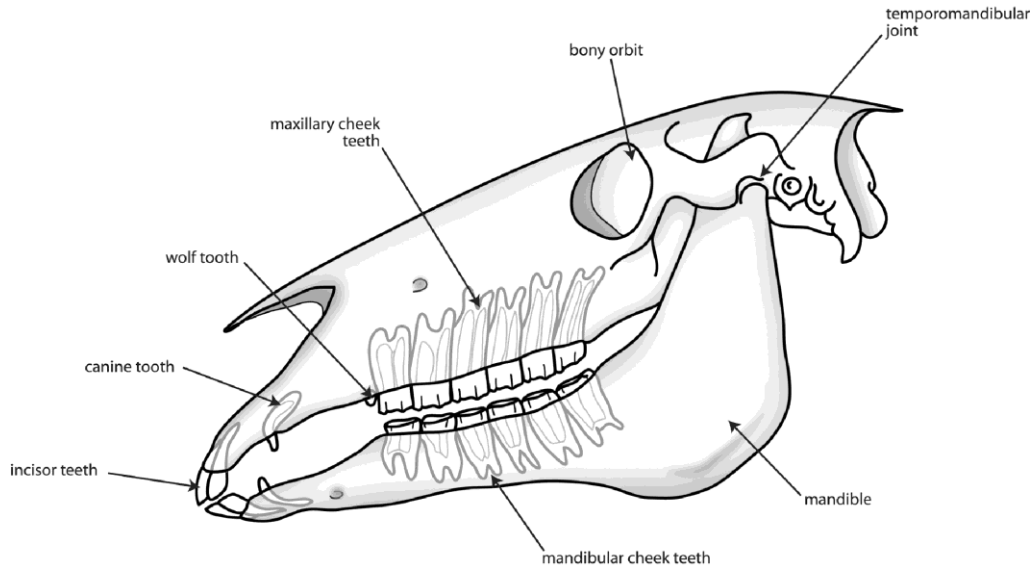


# Hunter Stallion Station

---

## Equine Veterinary Services

### Equine Dentistry Guide



The Equine Skull

Horses and ponies are efficient herbivores and one of the key adaptations that evolution for a life of grazing has equipped them with is a set of hardwearing and specialized teeth.

#### What sort of teeth do horses have?

Equine dentition can be broken down into the following classes of teeth:

**Incisors:** Horses have 6 upper and 6 lower incisor teeth. These are simple in structure, deep-rooted and used to grasp and tear herbage.

**Canines:** Canine teeth or 'tushes' as they are more commonly known are the short and often-sharp teeth found in the gap or 'diastema' between the incisor teeth and cheek teeth on both the upper and lower sides of the mouth. Although generally only found in male horses, small canine teeth can also be found in some mares. Canine teeth erupt at around 4-5 years of age. The original purpose of canine teeth was as fighting weaponry and as such they serve no useful function in the modern horse.

**Wolf teeth:** Wolf teeth are small (often tiny) teeth that can be found immediately in front of the first upper cheek teeth. They erupt at 6-18 months and vary considerably in size and position; they can also rarely be found in front of the first lower cheek teeth. Not all horses have wolf teeth and not all of those that do have fully erupted wolf teeth on each side. Wolf teeth can be considered as an evolutionary dead-end having once been 'molarized' teeth and serve no useful purpose in the modern horse.

Cheek teeth: Horses have evolved dentition that allows them to spend a large part of their lives grazing on abrasive grasses. The teeth that do all the work grinding these grasses to prepare them for digestion are the cheek teeth. Horses have a total of 12 premolar and 12 molar teeth divided into an upper and lower row each of 6 cheek teeth on both the left and right sides of the mouth. While the premolar teeth have a deciduous (or 'babytooth') precursor, which is ultimately shed as a 'cap', essentially adult premolar and molar teeth have the same appearance and function. Although both of the cheek teeth arcades are composed of 6 individual teeth, in the healthy horse these teeth erupt in a tightly packed unit, essentially acting as a single grinding tooth. The cheek teeth of young horses have a large amount of 'reserve crown' below the gum and for the majority of the horse's life these teeth will erupt into the mouth to make up for the wearing down of the grinding surface of the tooth. In old age, this constant eruption eventually results in some teeth wearing completely out. Cheek teeth are a composite of three hard materials: enamel, dentin and cementum that complement each other to provide a uniquely abrasive surface ideal for breaking up food material.

### What is mastication?

Mastication means the process of chewing food. In the horse, food is grasped by the incisor teeth and moved back to the cheek teeth arcades by the combined action of the tongue and cheek muscles. The chewing motion of the mouth is controlled by several large muscles that act to slide the upper and lower cheek teeth against each other, breaking up the bolus of food before it can be swallowed.

### Why do horses need routine dental care?

Horses have survived perfectly well for a long time without human intervention so it is sensible to question why it is necessary to perform equine dentistry at all. The answer lies not so much with the horse but with the circumstances in which it now exists. As we have discussed above, horse dentition is superbly adapted for a life of grazing on tough grasses for up to fourteen hours a day. Domestication has brought with it altered feeding patterns and many horses now spend little time grazing due to the feeding of energy dense concentrates. Not only is less time spent chewing but it



has also been shown that the type of feed given to the horse can alter its chewing pattern. The same features that make the cheek teeth ideal for a life of free-range grazing (such as continual eruption and abrasive grinding surface) can produce problems in the domesticated animal. The cheek teeth of the upper jaw are set wider than those of the lower jaw and with the altered pattern of chewing, sharp points can develop on the outer edges of the upper cheek teeth and the inner edges of the lower cheek teeth. These can rub and catch against the cheeks and tongue causing ulcers.

In addition to the effects of an altered diet on the domesticated horse, horses are often asked to carry a bit, ride in collection and be responsive to cues. It is not hard to understand why oral comfort can prove to be so important. Horses these days are also living much longer than they might have done in the natural state. It is not uncommon for horses to 'outlive' some of their teeth and routine dentistry in older horses and ponies focuses on preserving good function for as long as possible.

## What does routine dental rasping ('floating') involve?

The process of removing potentially harmful sharp points and edges from the cheek teeth is called rasping or 'floating'. This is undertaken on a regular basis depending on the age of the horse and the health of the mouth. Before rasping the teeth a thorough examination of the mouth should first be performed. This can only be done properly by using a device called a speculum or 'gag' to safely keep the mouth open. This allows the practitioner to look and feel inside the horse's mouth to check not only for sharp points but also for other problems such as broken or missing teeth. Only once the mouth has been examined will the teeth be rasped. There are many different types of dental rasps available and the practitioner will have a range of instruments to allow work to be performed on teeth in various parts of the mouth. Horses generally tolerate rasping of the teeth very well, but occasionally sedation may need to be administered by a veterinarian should the horse resent any of the procedures, to allow them to be completed. Floating of the teeth can also be undertaken using motorized equipment. Motorized equipment in the right hands can be a very effective tool for both routine floating and the specific management of dental irregularities. In the wrong hands, however, it can cause much damage to the horse either through over-heating or over-reduction of the teeth or laceration of soft tissues within the mouth.

## How often should routine dentistry be carried out?

Although it is sensible for foals' teeth to be checked at a young age to pick up any developmental abnormalities, often the first thorough dental examination and rasping occurs at 18 months to 2 years of age. Young horses can have surprisingly sharp teeth and it is wise to make the mouth comfortable prior to breaking-in. The frequency of dental examinations varies according to individual needs but as a general rule of thumb more frequent examinations are necessary in younger animals. Horses will shed 12 cheek teeth caps and 12 incisor caps and will erupt 36 or more permanent teeth before the age of 5. This 'flurry' of activity frequently means that there are sharp or loose teeth in the young mouth and 6 monthly examinations are commonplace.

When horses gain a mature mouth often annual visits are sufficient to keep the mouth comfortable and balanced however some horses need more frequent care, particularly if there are any abnormalities of growth such as overlong or displaced teeth. When horses reach old age it is very important not to be too aggressive when rasping in order to preserve what grinding surface area remains in the mouth. For this reason management of old horses often simply involves checking for loose or obviously diseased teeth.

## What should I do about my horse's wolf teeth?

Wolf teeth are small teeth that sit immediately in front of the first upper cheek teeth and much more rarely the first lower cheek teeth. They come in many shapes and sizes and are usually present by 12-18 months of age although not all horses have them. Most of the time wolf teeth do not cause problems, but traditionally owners and riders have considered them to be a potential cause of biting problems. When wolf teeth are taken out it is usually because of this historical dislike for them rather than any demonstrable problems. Having said that wolf teeth can sometimes be sharp or mal-erupted and it can seem illogical to make the rest of the horse's mouth comfortable but leave a troublesome wolf tooth in place where it might pinch the cheek with bit pressure. Sometimes the presence of wolf teeth can impair the thorough rasping of the first cheek tooth and in these cases removal of wolf teeth is also justified. Removal of wolf teeth is sometimes simple and sometimes difficult and often requires sedation by a veterinarian and even the administration of local nerve blocks.

## How accurately can the age of horses and ponies be determined by examining their teeth?

In the past it has been common to age horses by the appearance of their incisor teeth. The eruption and appearance of various features of these teeth have been associated with particular ages, however it is now known that the technique is inherently inaccurate. A reasonable degree of accuracy exists up until the age of around 10 years, however after that it is best to talk in age groups of 5 or so years. Gone are the days when a veterinarian would confidently state the exact age of a horse by inspecting its incisors.

## What about 'caps'?

'Caps' typically refer to the thin remnants of the deciduous (baby) cheek teeth. Horses will lose a total of 12 cheek teeth caps generally between the ages of 2.5 and 4.5 years of age. Most of the time these are shed perfectly naturally, however occasionally a young horse will salivate or show signs of mouth pain due to a partially dislodged or loose cap. Removal of these is simple and readily undertaken at a routine dental examination. Premature removal of caps is not advisable as it can damage the underlying 'adult' tooth.

## What advanced dentistry is now practiced for horses and ponies?

For the most part horses get through life perfectly happily simply with regular routine floating. There are occasions however when problems may arise:

**Development abnormalities:** some horses develop teeth that for one reason or another erupt abnormally. The most common of these is the 'parrot-mouthed' horse that results in an overbite; severe cases can have incisor teeth that do not meet at all. While these incisor problems rarely cause the horse discomfort, the same horses often have a misalignment of the cheek teeth arcades. Because the cheek teeth are designed to wear against each other, any unopposed tooth or part of a tooth can become overgrown with time. In some cases large 'hooks' can develop at the front and back of the mouth. On a similar note, horses are sometimes encountered that have an uneven number of teeth (due to a missing tooth or extra tooth) and if left untreated the resulting overgrowth can cause oral discomfort and restriction of chewing.

**Fractured teeth:** fractured cheek teeth are not an uncommon finding in horse's mouths. Sometimes the cause of these fractures can never be determined but in a large number of cases it is the result of the normal forces of chewing acting upon a tooth already weakened by disease. Fractured teeth do not cause problems in all cases, however on occasion they can result in painful chewing and even infection and death of the entire tooth.

**Cheek tooth infection:** if a horse develops a swelling on the face or jaw or a sinusitis the underlying cause may be an infection of one of the cheek teeth. Infected cheek teeth often require removal either by standing surgery or under general anesthesia. Evaluation and treatment of dental infections can be a complicated business and it is for this reason that they are often undertaken at specialist veterinary centers that have access to radiographic, scintigraphic, endoscopic and surgical facilities.

**Periodontal disease and diastema:** the cheek teeth of most horses erupt as a tight unit, effectively acting as a single tooth in each arcade. However, horses are occasionally encountered with gaps between some of the teeth, either due to the loss of a tooth or to poor eruption. Food may become trapped in these gaps (called 'diastema'), resulting in infection, gum disease and sometimes even tooth loss. Affected horses may suffer pain to the extent that they lose weight. Management may be problematic and ongoing treatment is often necessary.

## Who should I ask to look after my horse's teeth?

In the United States regulations vary from state to state regarding the practice of equine dentistry. It is always best to ask your veterinarian for a recommendation.

**For more information on equine dentistry, and to make an appointment for your horse, call Hunter Stallion Station at (916) 687-6870 or send an email to [info@hunterstallion.com](mailto:info@hunterstallion.com).**